

Hypothesis.

**The importance of a histological diagnosis when diagnosing
and treating advanced cancer.**

**Famous patient recovery may not have been from metastatic
disease.**

Ian E Haines

Ray M Lowenthal

Correspondence:

Dr Ian E Haines

Melbourne Oncology Group
Suite 45
Cabrini Medical Centre,
Malvern 3144
Australia

Ph: 03-9509-3744

Email: <iehaines@bigpond.net.au>

This is an Accepted Article that has been peer-reviewed and approved for publication in the *Internal Medicine Journal*, but has yet to undergo copy-editing and proof correction. Please cite this article as an "Accepted Article"; doi: 10.1111/j.1445-5994.2011.02686.x

Over the last 33 years, mystery has surrounded the diagnosis and treatment of a very influential Australian patient. In the long gap between amputation of his leg for osteogenic sarcoma and successful treatment for widespread tuberculosis, he was told he had advanced and incurable metastatic sarcoma. Details of his recovery and the treatments used have been extensively described. An alternative hypothesis is advanced to explain his recovery. This hypothesis is advanced for two reasons. The first is to underline the modern recognition of the need to consider diagnostic investigations, including biopsy, before assigning the diagnosis of advanced cancer to any patient. This principle is especially vital in cases where two diseases can present in the same way. . The second is that there a risk that if diseases are incorrectly labelled, incorrect treatments may be given. This can lead to misleading interpretations being made about non-traditional treatments providing “cures,” which can influence the decision-making of patients seeking answers and even lead them away from potentially curative traditional treatments.

As treatments for cancer become more sophisticated and more narrowly targeted, there is a changing paradigm in the management of advanced malignancy. This is that new lesions that develop in patients with a prior cancer diagnosis should be considered for biopsy before the diagnosis of recurrent or metastatic disease is accepted. There are several reasons: firstly the need to differentiate non-malignant conditions that can mimic cancer; (1) secondly the awareness that patients who have had one cancer are often at increased risk of a second (different) cancer; (2) and thirdly the need to determine concordance of tumour markers between primary and secondary cancers, given their therapeutic implications. (3)

That current practice is changing, is relevant to the intriguing anecdote of one of Australia's highest profile and most influential cancer survival stories. The well-known history, details of which have been made public by the patient himself and by his chroniclers, involves a man who was originally diagnosed with osteogenic sarcoma in late 1974 at age 24, and treated by full right leg amputation shortly thereafter. Subsequently a series of events developed that were considered to have been due to metastatic disease. At one time he was given a two week prognosis but nonetheless he went on to survive 'against the odds', using a multitude of treatments. The recent publication of a 30-year follow-up, (4) and a subsequent challenge to that publication's accuracy, (5) add to the mystery.

Two contrasting hypotheses have up to now been advanced to explain the patient's recovery. The first is that he was cured of very advanced, metastatic osteogenic sarcoma by a variety of traditional and non-traditional treatments. Some of the non-traditional treatments have been published and followed by many Australian patients with cancer over the past 30 years in the hope of achieving a similar outcome. (4, 6-9) The second is that the patient recovered from both advanced metastatic cancer and disseminated mycobacterial infection, either tuberculosis (TB) or BCG'osis. The proponents of this theory are divided on whether the disseminated mycobacterial infection occurred contemporaneously with the advanced cancer (5) or after the advanced cancer had gone into remission. (4)

However, the latest chronology of events,(5) if correct, raises the possibility of a third hypothesis. This is that the patient, having been cured of localised high-grade osteogenic sarcoma of the leg by surgery in 1975, then developed advanced TB alone without metastatic cancer. The possibility of inaccuracy in the patient's diagnosis has been alluded to previously. (10) Under this hypothesis, which we believe to be the most likely of the three, the patient's illness may have been wrongly labelled as advanced metastatic cancer for three years before TB was diagnosed and successfully treated in 1978-79.

The ability of disseminated TB to mimic advanced cancer is well documented (11-15). The publicly available medical facts that support the third hypothesis are summarised in the timeline in Fig 1 and are as follows:

1. The patient had full right leg amputation in January 1975 for a histologically proven osteogenic sarcoma. *Comment: This surgical procedure was carried out with the aim of cure.*
2. In November 1975, the patient consulted his original surgeon because of new pelvic symptoms. He had xrays and was found to have a large right pelvic mass that was presumed to

be due to metastatic cancer but was not biopsied. Chest x-rays revealed enlarged mediastinal nodes. He was given a prognosis of 3-6 months (7,9,16). *Comment: It is noteworthy that lymphadenopathy is a rare manifestation of metastatic osteosarcoma; typically the first presentation of metastatic osteosarcoma is with pulmonary secondaries (90 per cent). (17) The other common site of first metastasis is bone. (18)) In the largest published series, 'regional' metastases occurred in only 5 of 501 metastatic relapses. (19) On the other hand, these developments are quite consistent with the onset of disseminated TB(20).*

3. By February 1976, the patient had also developed severe drenching sweats nightly, dramatic weight loss, and severe left leg pain interpreted as sciatic pain. Xrays confirmed masses in his right ilium, sacrum and L5 vertebrae. These areas were treated with three intensive sessions of radiation therapy in February 1976. Chest x-ray in early March 1976 showed a large left hilar mass with peripheral opacification in the left lung, *Comment: This constellation of symptoms and signs is more typical of a severe systemic infective process such as disseminated TB than metastatic disease, with the lesions in the right ilium, sacrum and L5 vertebra being consistent with large tuberculomas.. (5) (7) Importantly, a few days after completing radiation therapy, the hospital rang to say that the patient's x-rays had been re-examined and now they did not believe he had cancer in his pelvis and spine. There was no symptomatic or radiologic response to radiation therapy (7), an outcome that would be expected if the masses were non-malignant. The large residual osteoblastic mass in the pelvis (7) appears consistent with a healed tuberculoma.*

4. In March 1976, IVP confirmed right hydronephrosis. *Comment: Renal TB is the second most common extra-pulmonary manifestation of TB, second only to lymphadenitis, and is often associated with hydronephrosis. (21,22) We can find no record in the literature of hydronephrosis as a complication of osteosarcoma.*

5. At this time in February 1976, "Three new cancerous bony lumps were beginning to grow on the patient's breastbone." (7) and by September-October 1976, the patient had developed cough and haemoptysis. Large palpable masses were now present around the sternum and anterior ribs and a mass was again seen in the hilum of the left lung on chest x-ray (CXR) with inflammatory changes in the left lower lobe (7). *Comment: Haemoptysis and the described CXR changes are profoundly atypical for metastatic osteogenic sarcoma (which characteristically involves lung parenchyma and not the hila) and are more typical of infection such as a hilar tuberculoma with secondary bacterial or tubercular pneumonia in the left lower lobe. The left hilar and central and right chest wall masses were not biopsied before the patient received three months of intensive multidrug chemotherapy for what was presumed to be metastatic cancer. Although his oncologist felt that the lumps stopped growing on chemotherapy (7), these masses are consistent with tuberculomas, possibly in direct continuity with tuberculous mediastinitis. Tuberculous mediastinal lymphadenitis is a frequent manifestation of primary pulmonary tuberculosis. Extranodal extension may occur into adjacent structures such as the bronchus and chest wall and may form fistulae(23,24). One relevant case report describes a tuberculous sternal mass misdiagnosed as malignant disease (25).*

6. In mid 1977, the patient began coughing up blood and sputum containing what were interpreted as spicules of bone. (4, 7) At the same time, the chest wall lumps started to recede. *Comment: These "spicules" were not examined histologically and are consistent with inspissated pus from a left hilar tuberculoma (12,13,15) that has formed a fistulous connection to*

the left main bronchus. Equally likely, given the appearance of these “spicules”, is broncholithiasis, the presence of calcified or ossified material within the lumen of the tracheobronchial tree. This can be a rare consequence of calcific TB eroding into the bronchus. (26,27) The subsequent resolution of the palpable chest wall masses (7, 8) is consistent with discharge and resolution of a large multilobular tuberculoma, probably through a bronchial fistula. (23,24,27) As stated in the conclusions of two major manuscripts (23,24) tuberculosis may involve the lungs, airways, vessels, mediastinum, pleura, chest wall or any combination of these structures.

7. By March 1978, the palpable chest wall lumps had disappeared but the pelvic and left hilar lung masses remained unchanged and the patient had redeveloped intermittent, severe low back pain. X-rays at this time confirmed a large calcified right pelvic mass and a now very destructive process in the L5 vertebra.(7) Also, an incessant cough and drenching night sweats persisted(7). *Comment: All these developments are consistent with progressive and widespread TB.*

8. In June 1978, the patient had developed widespread joint aches and swelling. He saw a new oncologist in Adelaide, where he was then living, who did x-rays and told the patient that “all the metastases with bone in them had more or less disappeared.” However, he also informed the patient that he had TB and that he felt that, upon review of all his xrays, it had been present and undiagnosed for at least two years. He also diagnosed the severe widespread joint aches and swelling as hypertrophic pulmonary osteoarthropathy (HPO). The patient commenced a 12 months course of treatment for TB and quickly re-attained full health (5,7). *Comment: It is clear from this chronology that at least some of the patient’s disease manifestations which previously had been attributed to metastatic cancer were in fact due to TB. Intriguingly, HPO has been described as a rare manifestation of both pulmonary tuberculosis (28) and of pulmonary parenchymal metastases from osteogenic sarcoma (29). However, this patient had no radiologic pulmonary parenchymal masses consistent with metastatic osteosarcoma.*

A recent review looks specifically at the prognosis, case-fatality rate and duration of untreated HIV-negative TB in patients who have been incorrectly diagnosed. The duration of TB from onset to cure or death is approximately 3 years and appears to be similar in smear-positive or smear-negative TB. The ten year case-fatality rate is 70% for untreated smear-positive TB and 20% for untreated smear-negative, culture-positive TB. We do not have details of the smear or culture status of the patient described in this report.(30) The surgical findings at the time of left pleuropneumonectomy in 2004 of widespread adhesions, bronchiectasis and tuberculous cavitation and scarring (4) are very supportive of the above hypothesis. (24) The histological findings of mature cancellous bone and foci of coarse sclerotic and heavily calcified bone in the centrally located mass, 35 x 30 cm, surrounding the bifurcation of the left main bronchus are quite consistent with the sequelae of resolved benign inflammatory conditions such as tuberculomas that have also involved the pleura substantially.

This third possible hypothesis is advanced for two reasons. The first is to underline the modern recognition of the need to consider diagnostic investigations, including biopsy, before assigning the diagnosis of advanced cancer to any patient. This principle is especially vital in cases where two diseases can present in the same way. As Cantwell et al (11) state, in reporting another case of a patient with both osteogenic sarcoma and tuberculosis, “a high index of suspicion is urged to diagnose atypical cases”, particularly where it may help avoid the use of potentially cytotoxic

chemotherapy in the presence of undiagnosed active tuberculosis. Secondly there is a risk that if diseases are incorrectly labelled, incorrect treatments may be given. This can lead to misleading interpretations being made about non-traditional treatments providing “cures,” which can influence the decision-making of patients seeking answers and even lead them away from potentially curative traditional treatments.

In presenting this hypothesis we emphasise that we are not in any way criticising the patient’s medical attendants who unquestionably acted fully in accordance with the standards of the time. Indeed, the need to consider obtaining histological confirmation of presumed metastatic disease is only now becoming part of standard oncological practice. We note that one of the leading textbooks of oncology states in its latest edition in relation to possible cancer recurrence: “Whenever possible, tissue acquisition for diagnostic confirmation ... should be considered.” (31)

Whatever the correct diagnosis, we acknowledge the courage and determination of the patient that allowed him to recover from a prolonged and very debilitating illness. We especially note the psychological resilience that enabled him to overcome the dire prognosis he was given that fortunately turned out to be inaccurate.

Nonetheless, there is an aphorism, attributed to the late Carl Sagan, that exceptional claims require exceptional evidence. We contend that unequivocal evidence that the patient was cured of widespread metastases is lacking, and that the unusual treatments that were employed in this case cannot be held out as an example of a path to be followed by other patients with metastatic cancer.

ACKNOWLEDGEMENTS

We would like to thank Associate Professor Dennis Spelman, Head of Microbiology, Alfred Hospital, Melbourne and Drs Bill Downey and Ralph Zito. Senior Pathologists, Cabrini Pathology, Cabrini Health, Melbourne for their helpful comments and advice; Ms Grace Gawler, for checking that our interpretation of the chronology of events matched hers; and the staff of the Ian Potter Library, Alfred Hospital, Melbourne, for expert assistance with literature searches.

DISCLAIMER

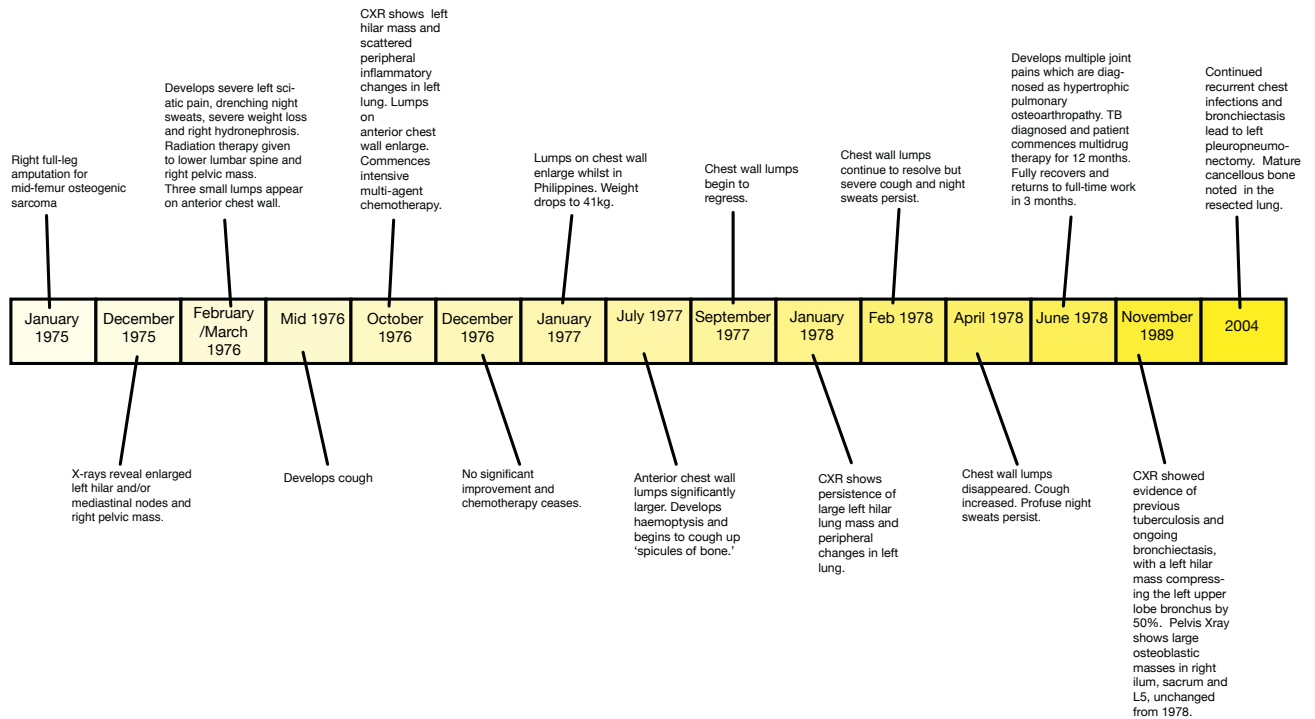
All Clinical details in this manuscript have come from publicly available sources, which have been cited. We did not use or have access to any privileged material.

REFERENCES

1. Grigg A, Landgren A. Infective mesenteric adenitis masquerading as relapsed non-Hodgkin's lymphoma. *Leuk Lymphoma*. 2004;45:2517-2519.
2. Zarate-Osorno A, Medeiros LJ, Kingma DW, Longo DL, Jaffe ES. Hodgkin's disease following non-Hodgkin's lymphoma. A clinicopathologic and immunophenotypic study of nine cases. *Am J Surg Pathol*. 1993;17:123-132.
3. Simmons C, Miller N, Geddie W et al. Does confirmatory tumor biopsy alter the management of breast cancer patients with distant metastases? *Ann Oncol*. 2009;20:1499-1504.
4. Jelinek GA, Gawler RH. Thirty-year follow-up at pneumonectomy of a 58-year-old survivor of disseminated osteosarcoma. *Med J Aust*. 2008;189:663-665.
5. Gawler GO. Cancer patients at risk from inaccurate clinical reporting in a high-profile alternative treatment story: comments and corrections. *Med J Aust*. 2010;193:371-373.
6. Meares A. Regression of osteogenic sarcoma metastases associated with intensive meditation. *Med J Aust*. 1978;2:433.
7. Allenby G, Gawler I. *The Dragon's Blessing*. Allen & Unwin; 2008
8. Gawler I. *You can conquer cancer*. New edition. Bookwise International; 2001
9. Gawler I. Cancer Patients find strength in self-help approach. *Australian Doctor* 3rd Sept 1993;24-27.
10. Lowenthal RM. Can cancer be cured by meditation and "natural therapy"? A critical review of the book *You can conquer cancer* by Ian Gawler. *Med J Aust*. 1989;151:710-715.
11. Cantwell B, Fennelly JJ, Masterson J, Lynch V. Hilar tuberculosis in a patient with osteosarcoma. *Postgrad Med J*. 1981;57:530-531.
12. Frouge C, Miquel A, Cochran-Priollet B, Adrien C, Blery M. Breast mass due to rib tuberculosis. *Eur J Radiol*. 1995;19:118-120.
13. Moyes EN. Tuberculoma of the lung. *Thorax*. 1951;6:238-249.
14. Muradali D, Gold WL, Vellend H, Becker E. Multifocal osteoarticular tuberculosis: report of four cases and review of management. *Clin Infect Dis*. 1993;17:204-209.
15. Ormerod LP, Grundy M, Rahman MA. Multiple tuberculous bone lesions simulating metastatic disease. *Tubercle*. 1989;70:305-307.
16. Gawler G. *Grace, grit and gratitude*. 2008. Ocean Shores, NSW. 416p. ISBN: 9780980394177.
17. Bacci G, Avella M, Picci P, Briccoli A, Dallari D, Campanacci M. Metastatic patterns in osteosarcoma. *Tumori*. 1988;74:421-427.
18. Bacci G, Ruggieri P, Picci P et al. Changing pattern of relapse in osteosarcoma of the extremities treated with adjuvant and neoadjuvant chemotherapy. *J Chemother*. 1995;7:230-239.
19. Kempf-Bielack B, Bielack SS, Jurgens H et al. Osteosarcoma relapse after combined modality therapy: an analysis of unselected patients in the Cooperative Osteosarcoma Study Group (COSS). *J Clin Oncol*. 2005;23:559-568.
20. Lawee D. Primary tuberculous inguinal lymphadenitis. *Can Med Assoc J*. 1969;100:34-36.

21. Carrillo-Esper R, Moreno-Castaneda L, Hernandez-Cruz AE, Aguilar-Zapata DA. Renal tuberculosis. *Cir Cir*. 2010;78:442-447.
22. Tanthanuch M, Karnjanawanichkul W, Pripatnanont C. Tuberculosis of the urinary tract in southern Thailand. *J Med Assoc Thai*. 2010;93:916-919.
23. Winer-Muram HT, Rubin SA. Thoracic complications of tuberculosis. *J Thorac Imaging*. 1990;5:46-63.
24. Kim HY, Song KS, Goo JM, Lee JS, Lee KS, Lim TH. Thoracic sequelae and complications of tuberculosis. *Radiographics*. 2001;21:839-58; discussion 859-60.
25. Mulloy EM. Tuberculosis of the mediastinum presenting as metastatic disease. *Thorax* 1995;50:1223-1224.
26. Chan ED, Morales DV, Welsh CH, McDermott MT, Schwarz MI. Calcium deposition with or without bone formation in the lung. *Am J Respir Crit Care Med*. 2002;165:1654-1669.
27. Kawamoto H, Kambe M, Takahashi H, Yamane K, Shibata S, Kuraoka T. [A case of cervical-mediastinal lymph node tuberculosis progressed to pulmonary lesion through a bronchial fistula]. *Nihon Kokyuki Gakkai Zasshi*. 1998;36:1053-1057.
28. Webb JG and Thomas P. Hypertrophic osteoarthropathy and pulmonary tuberculosis. *Tubercle* 1986;67:225-8.
29. Flueckiger F, Fötter R, Hauseger K, Urban C. Hypertrophic osteoarthropathy caused by lung metastasis of an osteosarcoma. *Pediatr Radiol* 1989;20(1-2):128-130.
30. Tiemersma EW, van der Werf MJ, Borgdorff MW, Williams BG and Nagelkerke NJ. natural history of tuberculosis: duration and fatality of untreated pulmonary tuberculosis in HIV negative patients: a systematic review. *PLoS One* 2011;6(4): e 17601.
31. Abeloff MD, Wolff AC, Weber BL, Zaks TZ, Saccini V, McCormick B. Cancer of the breast. In: Abeloff MD, Armitage JO, Niederhuber JE, Kastan MB, McKenna WG, editors. *Abeloff's Clinical Oncology*. Philadelphia: Churchill Livingstone; 2008. p. 1875-1944.

TIMELINE for IMJ-0177-2011. R1



imj_2686_f1