

## Cancer patients at risk from inaccurate clinical reporting in a high-profile alternative treatment story: comments and corrections

Grace O Gawler

**TO THE EDITOR:** I would like to correct some inaccuracies in an article by Jelinek and Gawler in the December 2008 issue of the Journal about a survivor of disseminated osteosarcoma.<sup>1</sup>

The article describes a 58-year-old man who was diagnosed in 1974, at the age of 24 years, with histologically confirmed high-grade osteosarcoma of the right femur. He underwent a full leg amputation in January 1975, but metastases recurred 11 months later, in December 1975.

The authors of the article misreported a sequence of medically significant events, altering the patient's actual history. (The correct chronology and early clinical history of the case have been published elsewhere.<sup>2,3</sup>)

The errors and omissions in the article by Jelinek and Gawler, together with the

correct sequence of events and relevant inclusions, are outlined in Box 1. In summary, the major errors in the article were as follows:

- **Timeline errors.** The authors stated that the patient first saw Dr Meares in September 1976, after chemotherapy had failed. In fact, the patient consulted Meares as a *first-line treatment* approach on 12 December 1975, and did not consider chemotherapeutic options until September 1976. The authors also stated that the patient had palliative radiotherapy in September 1976. In fact, the patient had only one course of palliative radiotherapy treatment, in February 1976.

- **Vegan diet.** The patient never followed a vegan diet.

- **Date of photographs.** The photographs in Figures B and C of the article by Jelinek and Gawler were taken on 7 July 1977 (Box 2), not at the time of first contact with Meares, as implied in the article.

An appraisal of the patient's symptoms, combined with an accurate clinical history, reveals a more plausible scientific hypothesis for his remission than the effects of diet

and meditation. Although diet and meditation may be adjuncts to a patient's well-being, it is unlikely in this case that they were curative, and certainly veganism was not a relevant factor. Immunotherapy with BCG vaccine treatments, the timing of symptoms and the patient's eventual diagnosis of tuberculosis could be associated with his remission, as postulated by his radiation oncologist in 1978.<sup>6</sup> There is extensive scientific literature about remission of cancer, including osteosarcoma, associated with febrile conditions.<sup>5,8-15</sup>

The patient's sporadic visits to doctors meant that metastases were not diagnosed histologically and much of the information reported on his case is anecdotal. Clearly, in this and other cases, unbiased investigative scientific research needs to be undertaken before reporting anecdotes and extrapolations as if they were fact. Teasing apart the errors in Jelinek and Gawler's story, now on the public record and almost medical myth, is an enormous task, but one that must be done, because correctly reporting the patient's clinical timeline is crucial in any discussion about the causes

### 1 Corrections to errors in the article by Jelinek and Gawler<sup>1</sup>

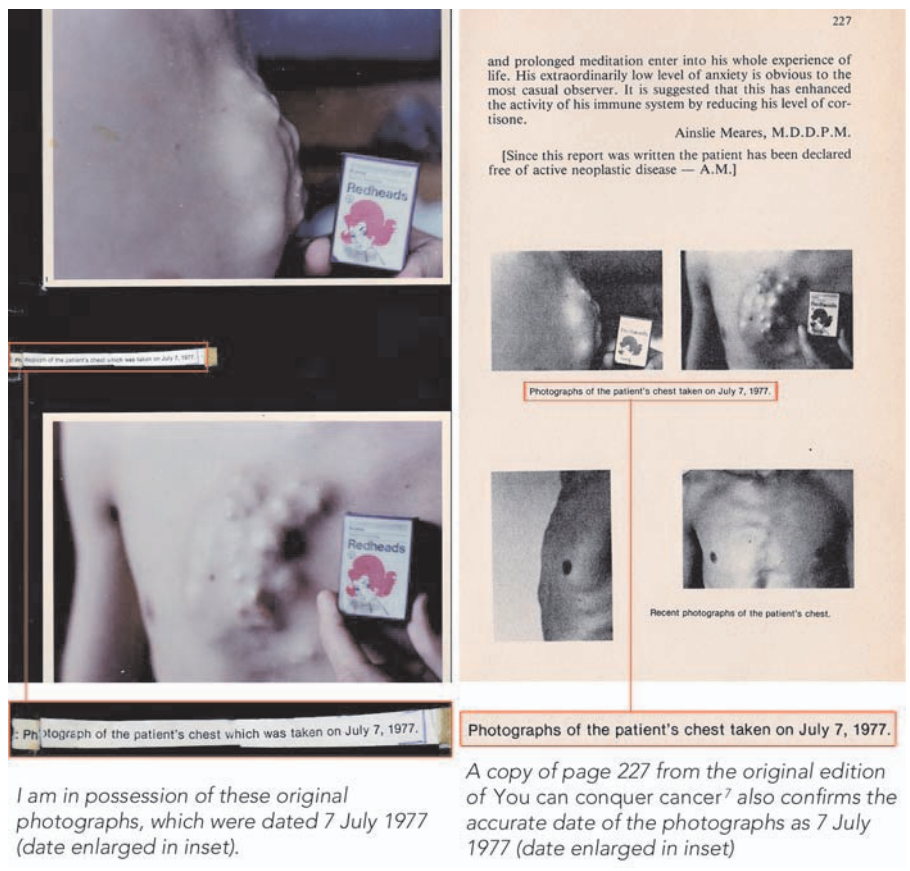
#### Errors and omissions in the article

- **December 1975:** widespread bony and pulmonary metastases were diagnosed.
- **September 1976:** "[the patient] underwent three cycles of palliative chemotherapy with vincristine, adriamycin, cyclophosphamide and dactinomycin, as well as brief palliative radiation therapy".
- **September 1976:** "He elected to discontinue these therapies as his condition deteriorated further."
- "The patient then consulted prominent psychiatrist and hypnotherapist Dr Ainslie Meares ...".
- **Dates of photographs shown in the article:** "When Meares first saw the patient, he had visible bony tumours protruding from his ribs, sternum (Figure B) and iliac crest, and was coughing up blood containing small spicules of bone (Figure C)."
- **Vegan diet:** "[the patient] adhered faithfully to a vegan diet".
- **First appearance of tuberculosis:** "Presumably related to immunosuppression from chemotherapy, he developed pulmonary tuberculosis in June 1978, and was treated for this condition for 12 months."

#### Facts, corrections and inclusions

- **December 1975:** an isolated metastasis in an inguinal node was diagnosed. The patient undertook the Gerson dietary regimen,<sup>4</sup> immunotherapy with BCG vaccine,<sup>5</sup> and the Meares intensive meditation program.<sup>6</sup>
- **September–October 1976:** growth of tumours on the sternum increased, and metastases were detected in the left lung. Coughing and haemoptysis were present.<sup>6</sup> Experimental chemotherapy (with adriamycin, vincristine and methotrexate)<sup>2</sup> was ceased at 10 weeks after December 1976. No radiation therapy was given at this time.
- Palliative radiotherapy was administered in February 1976, not September 1976.
- **December 1975:** the patient first consulted Meares. In February 1976, he abandoned the Meares meditation program.
- The 10-month discrepancy between December 1975 and Jelinek and Gawler's stated date of September 1976 (actual date, October 1976) alters the patient's medical timeline, implying that it was only after other treatments had failed that meditation began and played a key role in his recovery.
- The article by Jelinek and Gawler implies that the photographs in their Figures B and C were taken around the time when the patient first contacted Meares. The photograph in Figure B was actually taken on 7 July 1977, 19 months after his first contact with Meares. Tumours were not protruding from the sternum when Meares first saw the patient to begin meditation in December 1975, and there were no visible metastases. The coughing up of blood containing bone spicules (Figure C) began in mid 1977, not in the period between December 1975 and February 1976.
- The patient never followed a vegan diet. Veganism involves exclusion of all animal products. The Gerson regimen<sup>4</sup> includes dairy foods and calf liver juices. For the following 22 years, the patient's diet included seafood, dairy products and eggs.
- In 1978, an oncologist diagnosed advanced tuberculosis (TB) dating back to early 1976. (Previous x-rays were examined, showing evidence that TB had been present and undiagnosed for at least 2 years. The patient had very advanced TB by June 1978.<sup>6</sup>) The suspected cause was BCG vaccine treatments administered in December 1975, possibly exacerbated by chemotherapy and associated immunosuppression in late 1976. ♦

## 2 Original photographs of patient's chest taken on 7 July 1977



George A Jelinek and Ruth H Gawler

**IN REPLY:** In conjunction with the patient's memory, and teasing out details, where available, from medical records and investigations of over 30 years ago, we sought to piece together our follow-up story of a remarkable recovery from cancer as accurately as possible.<sup>1</sup> We did not attempt to reproduce the original case report in the *Journal*,<sup>2</sup> but rather were highlighting the long-term issues that can be associated with such recoveries. We thank Ms Gawler for attempting to clarify the original timelines. However, based on the medical records and published data, as well as checking further with the patient himself, it seems her letter does little more than muddy the waters in this case.

Ms Gawler claims the patient abandoned the Meares meditation program in February 1976. This is factually incorrect and misleading. The patient continued to use Meares' methods to meditate for 3 hours daily until he recovered, and has meditated at least 1 hour daily since then.

The timelines quoted around the photographs in Figures B and C in our original article<sup>1</sup> were based on information from Meares' 1978 article.<sup>2</sup> He was somewhat inaccurate, as is Ms Gawler, who claims the photos were taken in July 1977. This is incorrect. Figure B was photographed in July 1976 as chemotherapy was commenced. Figure C was photographed in 2008 and documents bony spicules coughed up during the first half of 1977, collected and retained by the patient.

Regarding the use of BCG vaccine treatments, the patient reports that none of the three tuberculosis (TB) specialists whom he consulted gave credence to Ms Gawler's suggestion that the onset of TB was related to the BCG vaccine. Ms Gawler further postulates that the remission could be linked to a febrile condition associated with TB. The patient did have severe night sweats (which may or may not have been accompanied by fever) over a period of 2–3 weeks in February and March 1976, at a time when he almost certainly had not yet contracted TB, and after which the metastases continued to grow rapidly. After this time, the patient never reported fevers that would make sense of this claim.

Ms Gawler claims that the patient's metastases were not diagnosed histologically and that much of the reported evidence is anecdotal. This is misleading and would surely surprise the involved surgeon, oncologist and other physicians, who used the best

of his remission and the flow-on effect to cancer patients and their treating doctors.<sup>16</sup>

**Acknowledgements:** I would like to thank Professor Ray Lowenthal for his assistance and feedback, and the staff of *Australian Doctor* for their assistance in retrieving archived material.

**Competing interests:** I am a co-founder of the Gawler Foundation and the former wife of the patient. I left the employ of the Gawler Foundation in 1996. My memoirs were published in October 2008 as an aid to correcting years of misinformation and misreporting about my former husband's remission.

**Grace O Gawler, Director**  
Supportive Care, Integrated Cancer Solutions,  
Gold Coast, QLD.  
grace@gawler.com

- Jelinek GA, Gawler RH. Thirty-year follow-up at pneumonectomy of a 58-year-old survivor of disseminated osteosarcoma. *Med J Aust* 2008; 189: 663-665.
- Gawler I. Cancer patients find strength in self-help approach. *Aust Doct* 1993; Sept 3: 25.
- Gawler I, editor. Inspiring people: stories of remarkable recovery and hope from the Gawler Foundation. Yarra Junction, Vic: Gawler Foundation, 1995.
- Gerson MA. Cancer therapy: results of 50 cases. New York: Station Hill Press, 1995.
- McCarthy EF. The toxins of William B Coley and the treatment of bone and soft-tissue sarcomas. *Iowa Orthop J* 2006; 26: 154-158.

- Allenby G. Ian Gawler: the dragon's blessing. Sydney: Allen and Unwin, 2008.
- Gawler I. *You can conquer cancer*. Melbourne: Hill of Content, 1984.
- Kleef R, Jonas WB, Knogler W, Stenzinger W. Fever, cancer incidence and spontaneous remissions. *Neuroimmunomodulation* 2001; 9: 55-64.
- Theilmann L, Meyer U, Kommerell B, et al. [Alpha tumor necrosis factor in the serum of patients with sarcoidosis, tuberculosis or bronchial cancer] [German]. *Pneumologie* 1990; 44: 735-738.
- Hortobagyi GN, Richman SP, Dandridge K, et al. Immunotherapy with BCG administered by scarification: standardization of reactions and management of side effects. *Cancer* 1978; 42: 2293-2303.
- Gkialis I, Kalantzis A, Lykourinas M. The response of urological tumours to immunotherapy. *J BUON* 2005; 10: 329-336.
- Terlikowski SJ. Tumour necrosis factor and cancer treatment: a historical review and perspectives. *Rocz Akad Med Bialymst* 2001; 46: 5-18.
- Wiemann B, Starnes CO. Coley's toxins, tumor necrosis factor and cancer research: a historical perspective. *Pharmacol Ther* 1994; 64: 529-564.
- Nauts HC. Osteogenic sarcoma: end results following immunotherapy (bacterial vaccines) 165 cases, or concurrent infections, inflammation or fever, 41 cases. New York: Cancer Research Institute, 1975. (CRI Monograph No. 15.)
- Hirshberg C, O'Regan B. Spontaneous remission: an annotated bibliography San Francisco, Calif: Institute of Noetic Sciences, 1993.
- Lowenthal RM. Can cancer be cured by meditation and "natural therapy"? A critical review of the book *You can conquer cancer* by Ian Gawler. *Med J Aust* 1989; 151: 710-715. □

available medical evidence at the time and cooperated in the preparation of our original article. The case is documented with a thorough medical history, the patient's surgeon and other specialists were consulted regularly, and accurate records were retained. Full details confirming the report are available in the patient's biography.<sup>3</sup> The metastases were thoroughly investigated and confirmed by the Peter MacCallum Cancer Centre in Melbourne and regularly tracked via x-ray. The original lesion seen on x-ray was diagnostic for osteosarcoma and the diagnosis was confirmed histologically by biopsy, and again after amputation.

The case history is certainly complex and compelling. The message is clear: unexpected recovery from disseminated cancer remains a possibility, and is likely to be influenced by lifestyle factors.

**George A Jelinek**, Professorial Fellow<sup>1</sup>

**Ruth H Gawler**, General Practitioner and Therapist<sup>2</sup>

<sup>1</sup> Department of Medicine, University of Melbourne at St Vincent's Hospital, Melbourne, VIC.

<sup>2</sup> Gawler Foundation, Yarra Junction, VIC.  
[george.jelinek@svhm.org.au](mailto:george.jelinek@svhm.org.au)

**Competing interests:** George Jelinek has run residential retreats for health practitioners and people with multiple sclerosis with the patient. Ruth Gawler is the wife of the patient, and has run residential retreats for people with cancer and multiple sclerosis with him.

1 Jelinek GA, Gawler RH. Thirty-year follow-up at pneumonectomy of a 58-year-old survivor of disseminated osteosarcoma. *Med J Aust* 2008; 189: 663-665.

2 Meares A. Regression of osteogenic sarcoma metastases associated with intensive meditation. *Med J Aust* 1978; 2: 433.

3 Allenby G. Ian Gawler: the dragon's blessing. Melbourne: Allen and Unwin, 2008. □